
Facial Sculpting and Tissue Augmentation

JEAN D.A. CARRUTHERS, MD,* AND ALASTAIR CARRUTHERS, MD†

*Department of Ophthalmology and †Division of Dermatology, University of British Columbia, Vancouver, British Columbia, Canada

BACKGROUND. Until recently, deep facial sculpting was exclusively the domain of surgical interventions. Recent advances in the available array of dermal and subdermal fillers combined with an esthetic appreciation by both surgeons and nonsurgeons alike of the positive effect of filling the volume-depleted face have led to an expansion in the indications for the use of soft tissue augmenting agents.

METHOD. Subdermal support of the lateral two-thirds of the brow, the nasojugal fold, the malar and buccal fat pads, the lateral lip commissures, and the perioral region, including the pre-jowl sulcus, all restore youthful facial contour and harmony. An important advance in technique is the subdermal rather than the intradermal injection plane.

RESULTS. “Instant” facial sculpting giving a brow-lift, cheek-lift, lip expansion, and perioral augmentation is possible using mod-

ern soft tissue augmenting agents. The softer, more relaxed appearance contrasts to the somewhat “pulled” appearance of subjects who have had surgical overcorrections. Treatments can be combined with botulinum toxin and other procedures if required.

CONCLUSION. Newer advances in the use of fillers include the use of fillers injected in the subdermal plane for “lunchtime” facial sculpting. Using the modern esthetic filler compounds, which are biodegradable but longer lasting, subjects can have a “rehearsal” treatment or make it ongoing. Some individuals, such as those with human immunodeficiency virus (HIV)-related lipoatrophy or those who desire to obtain a longer-lasting effect, may elect to use a nonbiodegradable filling agent.

ALASTAIR CARRUTHERS, MD, AND JEAN CARRUTHERS, MD, ARE CONSULTANTS AND INVESTIGATORS FOR AND HAVE RECEIVED HONORARIA FROM ALLERGAN INC. AND MEDICIS INC., ARE INVESTIGATORS FOR Q-MED, INC. AND FERNDALE LABS INC., AND ARE CONSULTANTS, INVESTIGATORS, AND ADVISORY BOARD MEMBERS FOR BIOFORM MEDICAL INC. ALASTAIR CARRUTHERS ALSO IS ON THE ADVISORY BOARD OF AND HAS RECEIVED HONORARIA FROM UNILEVER CANADA, IS ON THE ADVISORY BOARD OF AND IS A STOCK HOLDER OF ARTES MEDICAL, INC., AND IS AN INVESTIGATOR FOR RICHARD JAMES INC. JEAN CARRUTHERS, MD, IS ON THE ADVISORY BOARD OF ARTES MEDICAL INC, AESTHERA, AND LUMENIS, INC.

SOFT TISSUE augmentation with injectable filling agents is commonly used for reducing signs of facial aging. Initially used mainly in the perioral region, augmentation in other areas is rapidly increasing in popularity. A novel use for filling agents is to use their volume-occupying properties to replace lost subdermal fat and remodeled maxillary and mandibular bone to elevate the lateral brow, the mid-face, and the sublabial sulcus and mental contours, among other areas. The “push-fill” restores the youthful characteristics of the face without “pull” surgery, with less inconvenience and few complications. Using fillers for facial rejuvenation requires not only knowledge of specific fillers but also insight into the process and anatomy of aging. This article briefly reviews the new facial sculpting concepts for filler use.

Brow Ptosis and Surgical Brow-Lifts

The lateral brow becomes ptotic as the brow fat pad shrinks in size, and the lateral brow skin becomes elastotic with chronologic aging, photodamage, and repetitive action of the depressor fibers of the orbicularis oculi. The anatomy of brow ptosis has been extensively studied by Knize,^{1,2} and its treatment initially was primarily surgical. However, a purely surgical lift elevates the tail of the brow but does not restore its anterior projection. A purely surgical lift is two-dimensional, whereas the filler lift adds the anterior projection and the third dimension seen in youth (Figure 1). A variety of complications may be associated with forehead and brow-lifting procedures.³ In a recent retrospective review of 628 patients who underwent endoscopic brow-lift, Chiu and Baker found surgery to be less effective than desired in the majority of patients, with postsurgical complications, including alopecia, hairline changes, infected hardware, brow asymmetry requiring surgical revision, prolonged forehead or brow paresthesia, frontal branch nerve paralysis, and scalp dysesthesia.⁴

Address correspondence and reprint requests to: Jean Carruthers, MD, Cosmetic Surgery Inc., 740-943 West Broadway, Vancouver, BC, Canada V5Z 4E1, or e-mail: drjean@carruthers.net.

Complications that may be seen in the filler lateral brow-lift are both technique and substance related. Ideally, the needle is bent 45°, bevel up, and is gently inserted into the subdermal space (ie, replacing the brow fat pad) at the lateral brow cilia. The “push-ahead” technique is used,

allowing the subdermal region to be elevated by the forward movement of dermal filler rather than the tip of the needle (see Figure 1A). In this manner, bruising is extremely uncommon. In addition, spending some time molding the filler gives the best esthetic in terms of sym-

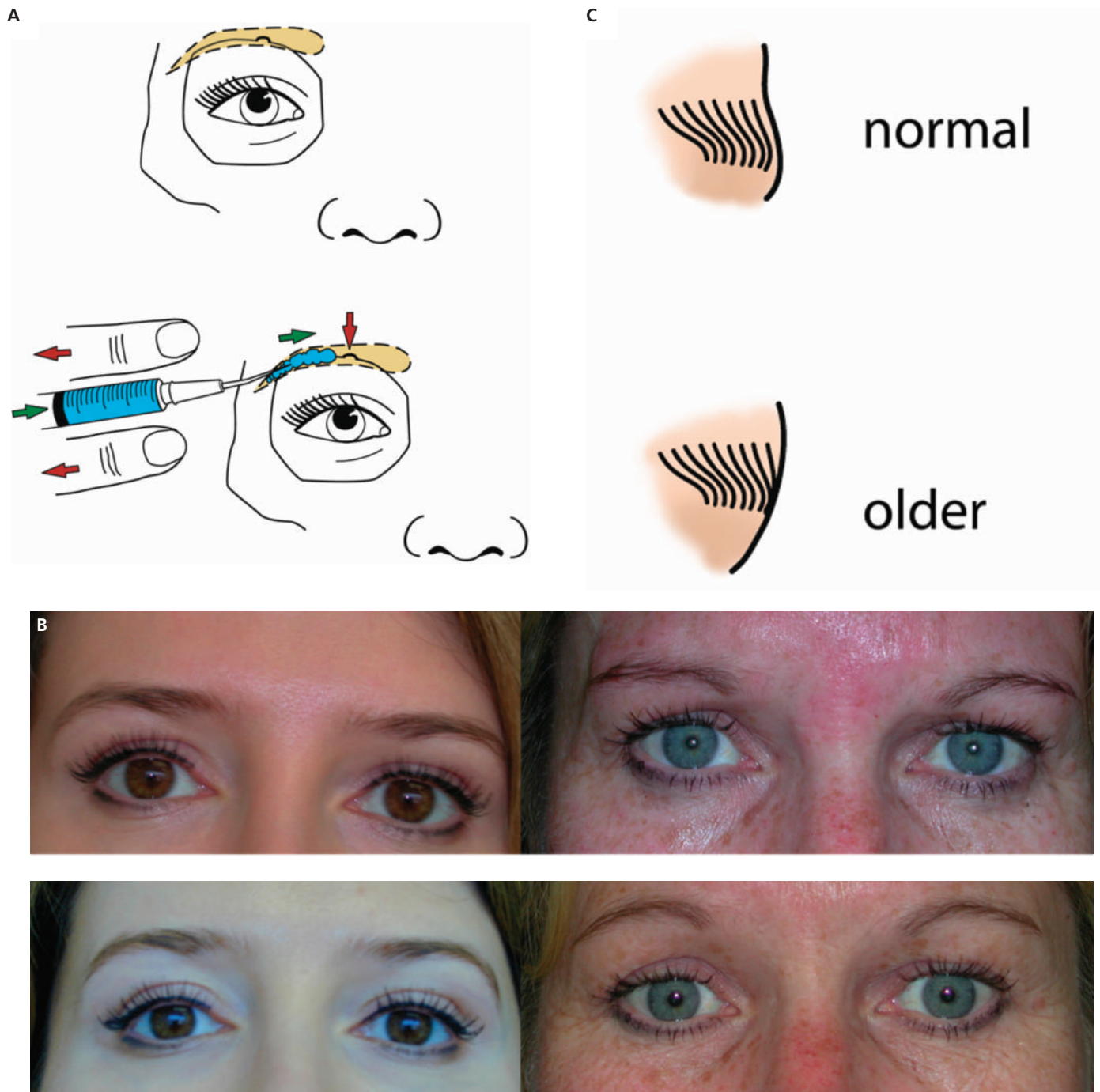


Figure 1. (A) Lateral brow-lift using the technique of subdermal insertion of the needle at the most lateral extent of the brow and delivery of the filler by the push-ahead technique to avoid bruising. (B) Before and after bilateral Restylane brow-lift from the temporal brow to the supraorbital notch. Note that the brow is more evenly arched and the upper eyelid platform is instantaneously enlarged in the after photograph in both subjects. (C) Filler lifting of the ptotic lateral brow restores the youthful anterior projection of the brow rather than simply elevating it, as with traditional surgical techniques.

metry and anterior projection. The lumping and bumping seen with hyaluronan injection in the lips can also be seen here. It is important to explain to subjects that 2 to 3 days of mild swelling and prominence of the implant are an expected part of the immediate local tissue response. Massage, ice, and oral prednisone 20 to 25 mg/d for 48 to 72 hours may be needed in more reactive individuals. We believe that highly viscous fillers, such as the hyaluronans, are ideal for this indication and that autologous fat and the collagen-based fillers need to be injected using a blunt cannula because they are much less viscous and can possibly embolize the periocular circulation. We have been performing this technique using hyaluronans with 27- to 30-gauge needles and the push-ahead technique since 2000 and have seen no vascular occlusive phenomena (see Figure 1, B and C).

Midface

Over the last 10 years, physicians have also focused their efforts on correcting the aging changes in the midface.⁵ Surgical lifting procedures of the midface provide an esthetic recontouring of the malar region, with more emphasis on the lower eyelid–cheek continuum and the

projection of the zygomatic ridges. In women, the visual expansion of the zygomatic midface emphasizes the heart-shaped esthetic of the classically beautiful female face. Although advances in cosmetic techniques—such as the reinforced orbitotemporal lift,⁶ combined cheek and midface lift with full-thickness temporal lower eyelid resection,⁷ endoscopic lift,^{8–11} midface sling,¹² and malar fat pad elevation^{13,14}—have improved patient outcomes, many surgical procedures result in prolonged periods of periorbital ecchymosis and edema, and consistent and symmetric improvements are still somewhat difficult to achieve, in particular for the less experienced surgeon.

Complications that may occur in the midface relate to judgment and marking of facial contours to achieve symmetry, multiple needle insertions that may provoke bruising and failure to use the push-ahead technique, and molding of the newly placed implant. In the malar area, the insertion plane is subdermal, and the region needing to be filled is marked, with the patient's assistance by holding a mirror, using a white soft lead eye pencil.

In the nasojugal fold, the filler material needs to be placed deep to the orbicularis oculi muscle just along the periosteum at the arcus marginalis so that there is no obvious cutaneous evidence of filler presence. In this way, the

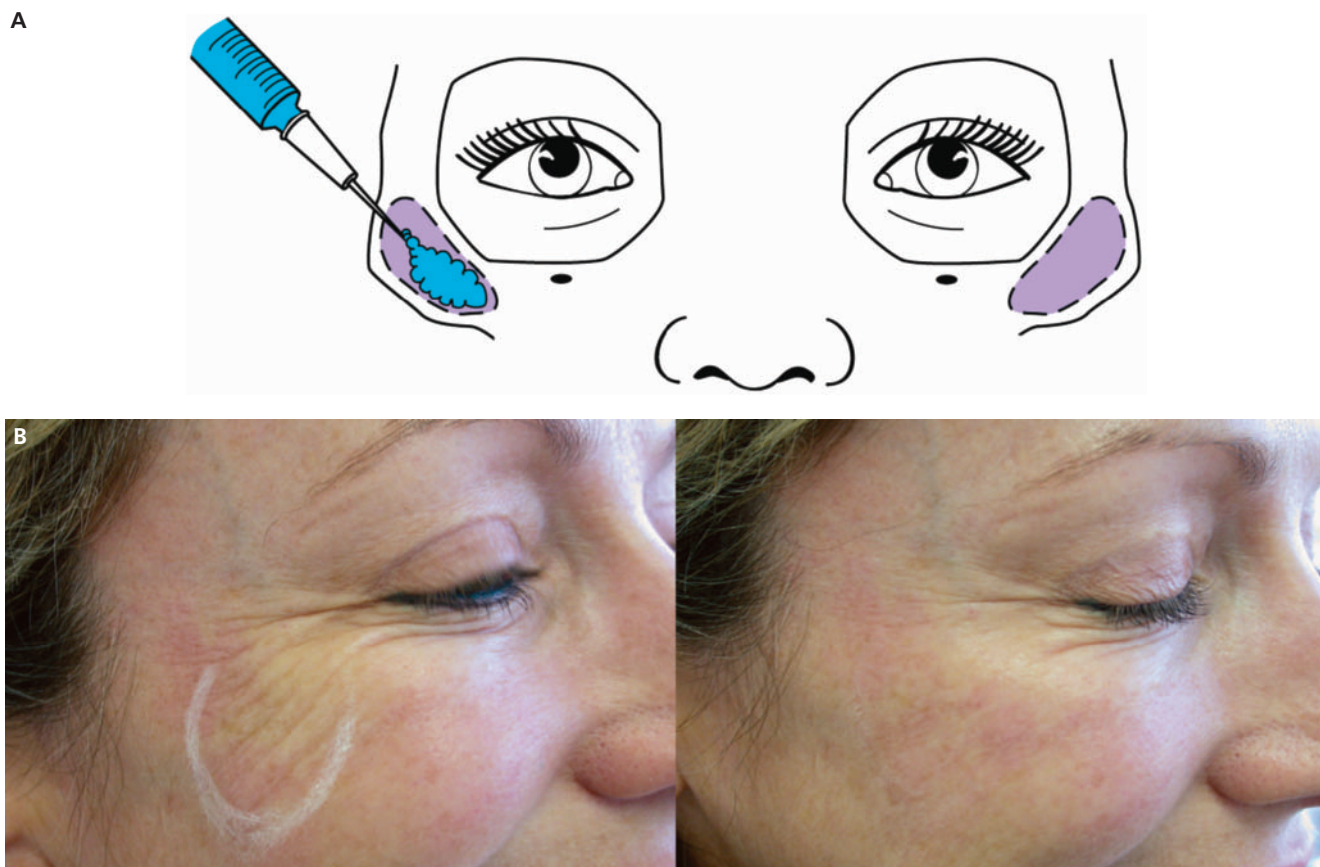

Figure 2. (A) Anatomic location of subdermal filler placement to restore normal malar convex contour. (B) Zygomaticomalar soft tissue augmentation using non-animal-stabilized hyaluronic acid (Restylane). Note the area to be augmented drawn on the subject using a soft eyeliner pencil (easily removable) to ensure post-treatment symmetry.

nasojugal fold is subtly distended and there is no tell-tale “blue ellipse,” as when the material is placed immediately subcutaneously. The reason for this is the unique thinness and delicacy of the periocular skin (Figure 2).

Lumping and bumping are mainly seen with the hyaluronan fillers. We note very transient similar side effects in the collagen-based fillers. Similar management of the situation with pretreatment explanation of the possible side effects turns them from complications to expected post-treatment outcomes.

The Aging Face

The pioneering work of Coleman,¹⁵ Amar,¹⁶ Donofrio,^{5,17,18} and Berman¹⁹ has led to the principle that age-related changes in the face may largely be improved by subcutaneous autologous fat augmentation and redistribution: the “sagging” skin associated with age is caused by the atrophy of subcutaneous fat and loss of remodeled facial bone, as well as by gravity.¹⁸ Loss of volume—particularly around the eyes and cheeks—cannot be completely corrected by traditional surgical procedures. This understanding has led to the emergence of a new form of rejuvenation: volume replacement with fillers in the brow and mid- and lower face, which subtly restores the face to youth (Figures 2 to 4).

Fillers for Facial Contouring

The recent surge in available injectables has shifted the focus of rejuvenation from surgical procedures, including use of autologous fat, to those that are more convenient and associated with fewer complications and little or no “downtime.” Soft tissue filler injections can be performed using only topical anesthetic agents and give an instant result with no downtime. A number of techniques aimed at restoring lost volume through the use of autologous and nonautologous fillers have demonstrated that rebalancing fat distribution or otherwise replacing volume to youthful proportions can restore the harmonious esthetic of the face. That it can be performed in a noninvasive manner may herald the future of facial rejuvenation.

Traditional Fillers

Bovine collagen has long been considered the “gold standard” in injectable fillers because of its ease of use, availability, affordability, and convenience. However, the possibility of allergic reactions to bovine collagen and the limited duration of effect have stimulated the continual search for more ideal fillers.²⁰ CosmoDerm and CosmoPlast (INAMED Aesthetics, Santa Barbara, CA, USA) are new bioengineered human collagen products approved for cosmetic use in Canada and the United States; in a study of 428 patients, no allergic responses were observed.²¹

Some believe that autologous fat grafting—a procedure that has been performed for more than 100 years—represents the ideal replacement for soft tissue atrophy, replacing volume and contours lost in the aging process.^{22,23} In 1997, Coleman promoted lipostucture—the placement of small amounts of fatty tissue in multiple tunnels—for a safe, long-lasting method of recontouring the face.¹⁵ The fat autograft muscle injection technique, developed by Amar¹⁶ and based on Coleman’s technique, involves the injection of adipose tissue within the muscles of facial expression in intricate layers of autologous fatty tissue with anatomic patented microcannulas and has shown improved long-term, esthetic results for facial rejuvenation.²⁴

In “fat rebalancing,” Donofrio has shown that replacing “missing” fat with autologous fat gives both a pleasing elevation and anterior projection of the lateral brow—a return to its youthful contour.^{17,18} Each rebalancing treatment, which addresses all facial areas, makes patients appear 2 to 5 years younger. Fat is harvested from the patient, frozen, and transferred in less than 0.1 cc aliquots under low injection pressures, weaving fat in a cross-hatched three-dimensional design through the muscle to the subdermis or, when injected periorbitally, placed conservatively deep to the periocular musculature.¹⁸ In total, patients undergo four to eight transfers over a year.

Although largely technique dependent, potential complications of autologous fat grafting include hematoma, fat necrosis, infections, vascular occlusion (including blindness and cerebral vascular accident), and the forma-

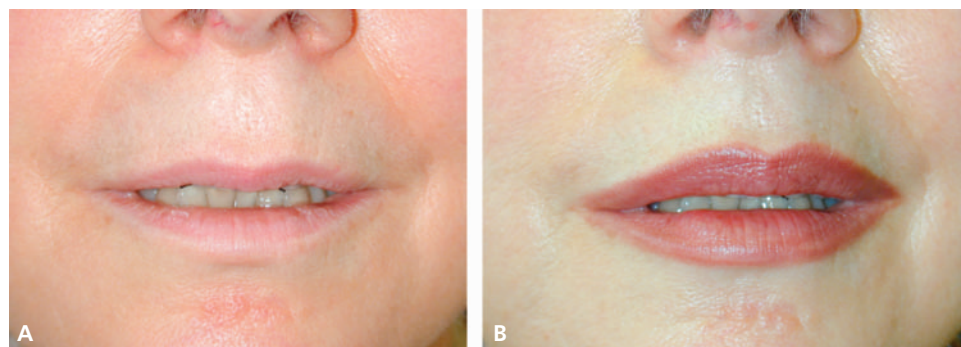


Figure 3. Traditional perioral (lip) augmentation using non-animal-stabilized hyaluronic acid (Restylane) (A, before; B, after).

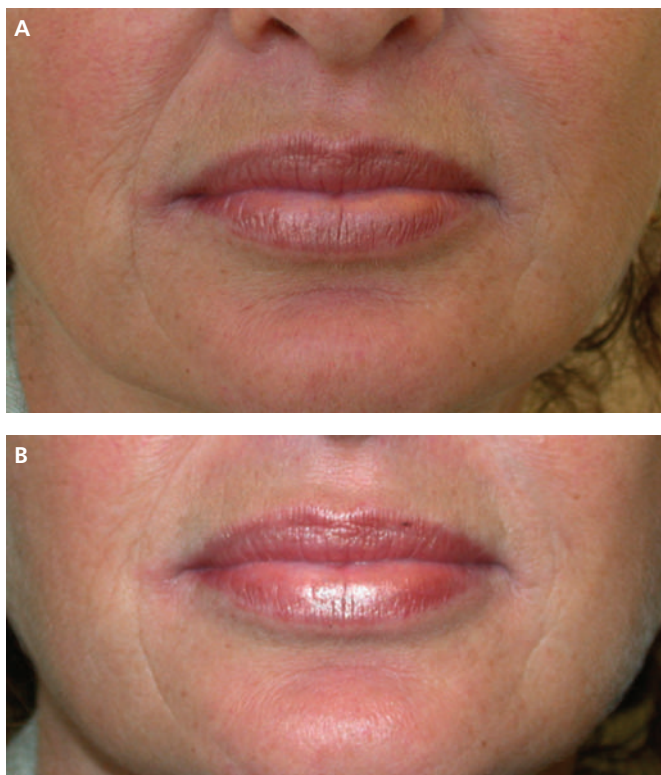

Figure 4. Support and enhancement of the lateral oral commissures and the creation of the commissural buttress as suggested by Coleman.²⁶ (A) Before and (B) 1 year after Perlane augmentation.

tion of cysts. Since the variable longevity of contour correction depends on technique, the amount of fat injected, and location, improvements in harvesting, handling, and the injection process may have an impact on positive patient outcomes.²² However, the fact remains that autologous fat grafting demonstrates unpredictable and sometimes temporary results.^{25,26} Moreover, harvesting and reinjecting fat are both significant procedures that are associated with downtime and the possibility of serious complications.

Hyaluronic Acid

Hyaluronic acid—a dimeric, cross-linked sugar molecule consisting of *N*-acetylglucosamine and glucuronic acid—is a key structural component of the skin that functions as a space-filling, structure-stabilizing, and cell-protective molecule. In cross-linked gel form, hyaluronic acid is hydrophilic and provides volume to easily fill in larger folds of skin around the mouth and cheeks (see Figures 2 to 4). Restylane and Perlane (Medicis Inc., Scottsdale, AZ, USA) are non-animal-stabilized hyaluronic acid gels that appear to provide durability and esthetic improvement that are superior to bovine collagen.²⁷ They may be useful adjuncts in facial cosmetic procedures^{28,29} and rarely cause

an allergic reaction. Restylane was approved for nasolabial fold augmentation by the US Food and Drug Administration (FDA) in 2003. Hylaform Plus (Genzyme Corp., Cambridge, MA, USA) is a naturally occurring cross-linked hyaluronan obtained from chicken combs; Hylaform was recently approved for esthetic use by the FDA (April 2004). The results typically last from 3 to 6 months, depending on the type of cross-linked hyaluronic acid used. The duration of the hyaluronic acid derivatives varies significantly, depending on the area injected. For example, mobile areas, such as the lips and lower nasolabial folds, have a shorter duration than less mobile areas, such as the cheeks, zygoma, and chin or those areas the mobility of which is affected by botulinum toxin.

Complications and Contraindications

The temporary nature of hyaluronic acid—an advantage in itself—is both the primary advantage and disadvantage for patients seeking a longer-lasting effect. However, the guarantee of eventual dissipation can be a reassurance, especially to esthetically naive patients who have never experienced facial rejuvenation. Intramuscular or subperiosteal injections are not recommended because much of the filler will be absorbed. Likewise, injections into dynamic areas associated with a great amount of movement, such as around the mouth, may lead to less satisfactory results because the motion will encourage absorption.³⁰ Injection-related adverse effects—bruising, erythema, pruritis, discoloration—are common and should be described pre-treatment to the patients as expected sequelae that are in no way unexpected complications.

Delayed skin reactions have been reported postinjection.³⁰ Recent publications have documented intermittent swelling and granulomatous reactions,^{30,31} and the use of impure or contaminated material can result in infection or foreign body reaction.³² However, granulomas often respond to injected corticosteroids, topical antihistamines, and digital pressure or manipulation.³⁰

Silicone Oil

Highly refined and purified silicone oil (Silskin, Richard James Inc, Boston, MA, USA) is currently the subject of a multicenter clinical trial.³³ A similar product, Silikon 1000 (Alcon Pharmaceuticals, Fort Worth, TX, USA) has been successfully used to restore normal contour in human immunodeficiency virus (HIV)-associated facial wasting.³³ Prior to treatment, individuals bear a stigma on their faces, which is characteristic of HIV infection. After treatment, subjects are able to return to normal work and social activities, having discarded that stigma (Figure 5).

Injectable silicone oil is currently in use, but this is mainly restricted to indications such as facial wasting because of the concern over long-term complications. The remote possibility of silicone granuloma is enough to discourage many physicians from using this agent.

Polymethylmethacrylate Microspheres

Artecoll (to be marketed in the United States after FDA approval under the name Artefill; Artes Medical, San Diego, CA, USA) is a suspension of polymethylmethacrylate (PMMA) microspheres in 3.5% bovine collagen solution. It is available in Canada and Europe and successfully corrects atrophy of the malar fat pad and adjacent subcutaneous fat (Figure 6).^{34,35} After subdermal (or, in severe cases, epiperiosteal) injections, the collagen solution eventually dissipates, leaving behind the nonbiodegradable PMMA microspheres. The volume to be injected depends on the depth and size of the depression; generally, at least two to four injection sessions are required. Given that the product (but not the correction) is permanent, one does not want to overcorrect the defect. Instead, partial correction, followed by reinjection after a few months, will produce a smoother, more natural appearance.

Complications and Contraindications

Injections of Artecoll are not recommended for areas of thin skin (eg, lower eyelid or neck). With lip augmentation, or in any other areas of repetitive movement, beading, palpability, and visibility of the implant may occur. Artecoll facial injections have been reported to cause the

delayed development of granulomatous reactions,³⁶ and improper placement intradermally (rather than into the upper levels of the subdermis) or too aggressive injections can lead to beading, ridging, and nodule formation and can cause disfigurement, which is reversible only by surgical excision.³⁰ Conservative amounts of Artecoll and a long interval between injections are recommended.³⁷ Even with a conservative approach, granulomas can appear months—even years—after treatment. Although the incidence is low, their potential occurrence must be part of the subject's informed consent process. They appear to respond to intraleisional triamcinolone injections,^{30,38} but other treatments, including surgery, may also be necessary. Contraindications include allergies to bovine collagen, thin, flaccid skin or atrophic skin disease, and keloids. Skin testing prior to injection is mandatory because of the bovine collagen vehicle.

Technique

The injection technique for Artecoll is different from that used for biodegradable fillers. First, the optimum results are obtained by subdermal and not intradermal injection levels. Second, it is unwise to aim for a full correction with Artecoll because the body responds better by being able to

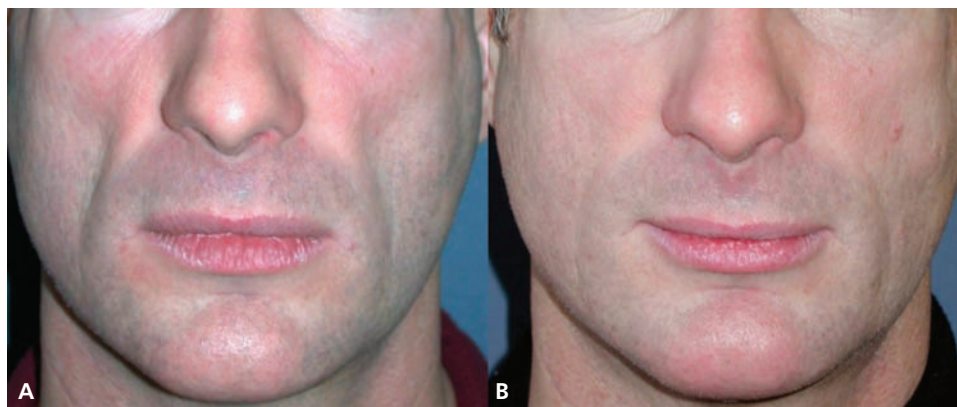


Figure 5. Repeated sequential purified silicone oil injections using the microdroplet technique restore subjects with chronic facial wasting to normal appearance and social function (A, before; B, after).

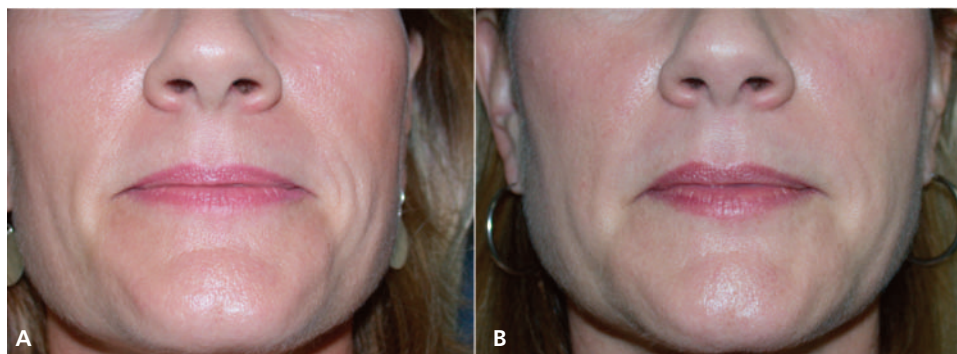


Figure 6. Artecoll under correction: injection in the subdermal plane to give a stepwise sequential esthetic augmentation (A, before; B, after).

encapsulate a smaller quantity of product more frequently (see Figure 5).

Temporal Brow-Lift

The skin is anesthetized with topical LMX 5% or Betacaine ointment and inspected for the underlying vasculature. The filler product of choice for each individual is chosen—usually Restylane or Hylaform Plus for the first treatment. We prefer to use the hyaluronan fillers in this area because of the greater tendency of the material to self-agglomerate and its ability to be gently molded postinjection.

A soft white or colored eye pencil is used to draw the ellipse into which the filler will be injected (N. J. Lowe, personal communication of his daughter's observation, 2003). The needle is bent at a 25° angle, bevel up, pushed through the skin, and gently advanced into the subdermal plane. The product is injected by the “push-ahead” technique so that the filling agent dissects ahead of the needle. Usually, the initial injection is placed at the temporal end of the lateral brow cilia, and the injection volume is 0.2 cc. The needle is withdrawn and reinserted about 7 mm medial to the first. The product is further injected using the push-ahead technique to the lateral aspect of the supraorbital notch. The usual injection volume is 0.1 to 0.2 cc in this segment. The product is molded gently to recreate the natural projection previously created by the brow fat pad, and ice is applied. An instantaneous lateral brow-lift is observed (see Figure 1).

Midface Filler Lift

Hypoplasia of the zygoma or midface fat descent and atrophy rob the female face of the normal heart-shaped contour. The eye pencil is used to outline the area of the zygoma, requiring esthetic enhancement. The face is checked for asymmetry, and photographs are taken with the periocular muscles relaxed and then dynamic in a forced smile. Filler is injected into the subdermal space in each place, and the esthetic benefit is inspected by the subject in a mirror. Restylane, Perlane, and Hylaform Plus all work well in this region. Artecoll may also work well, but a smaller injection volume is used at each treatment, as is a “top-up” treatment in approximately 6 to 8 weeks. Photographs, relaxed and with full smile, are taken after the treatment (see Figure 2). Botulinum toxin type A (BTX-A; Botox) for the crow's feet may be injected at the same treatment session. The combined use of filler and BTX-A appears to extend the life of the filling agent in this region as in others.^{28,29}

Nasojugal Fold Lift

As the ligament of Lockwood relaxes and allows the globe to sit more inferiorly, the malar fat pad descends and often

appears to “split” along the orbitomalar ligament. The resulting unmasking of the nasojugal fold gives a “double bubble” contour to the lower eyelid–cheek continuum. Injection of a filler deep to the orbicularis oculi and anterior to the arcus marginalis allows a restoration of the normal sigmoid contour to the cheek lid continuum (Figure 7).

Perioral Augmentation or Rejuvenation

The perioral region was found on a 2002 consumer survey performed by Allergan Pharmaceuticals to be of slightly more concern to the female respondents than the glabella. The deflation of the vermilion lip with vertically oriented “lipstick lines,” the downturned mouth corner, and the deepening melomental fold give a negative, sour, and disappointed emotional projection, even though the individual may be feeling very positive emotionally (Figure 8).

For many years, the vermilion lip itself has been the primary esthetic target of the physician experienced with the use of injectable fillers. However, during a research project performed using hyaluronans in Vancouver in 2003, Dr. Arnold Klein taught us to expand the lip treatment concept from the center of the frame (the lips themselves) to the entire lower facial frame—to the mouth corners, the melomental folds, the mental groove seen in tooth-grinders, and the prejowl sulcus. His carefully thought-out approach was a success in that project³³ and in our subsequent lip and perioral injections in our practices (Figure 9).

The order of treatment we use is first to elevate the lip corners and then the melomental folds, creating a subdermal strut of support to lift the lateral commissures (see Figures 8 and 9).

We extend the inferior portion of the strut laterally to fill in the prejowl sulcus. Often, using this approach, the inferior half of the nasolabial fold no longer requires intradermal fill, and we concentrate on the “shadow sulcus” in the upper nasolabial fold at the lateral border of each nasal ala (see Figure 9). The key to the injection technique is to lay down a subdermal deposit of filler material so that the general contour is reestablished. Layering can be done subsequent to the subdermal sculpting.

Chin (Mental) Implant

Some patients desire a fuller chin so that it projects forward to line up with the lower lip with the face in the Frankfort horizontal. After photographing the face in the primary position and right and left lateral gaze, the filler is injected subdermally into the regions superior and lateral to the mentum. Typically, 0.2 to 0.4 cc is required per side. The fill here is a pleasing adjunct for more traditional lip augmentation.³⁰ BTX-A is usually injected right at the point of the mentum into the mentalis, and 3 to 5 U is

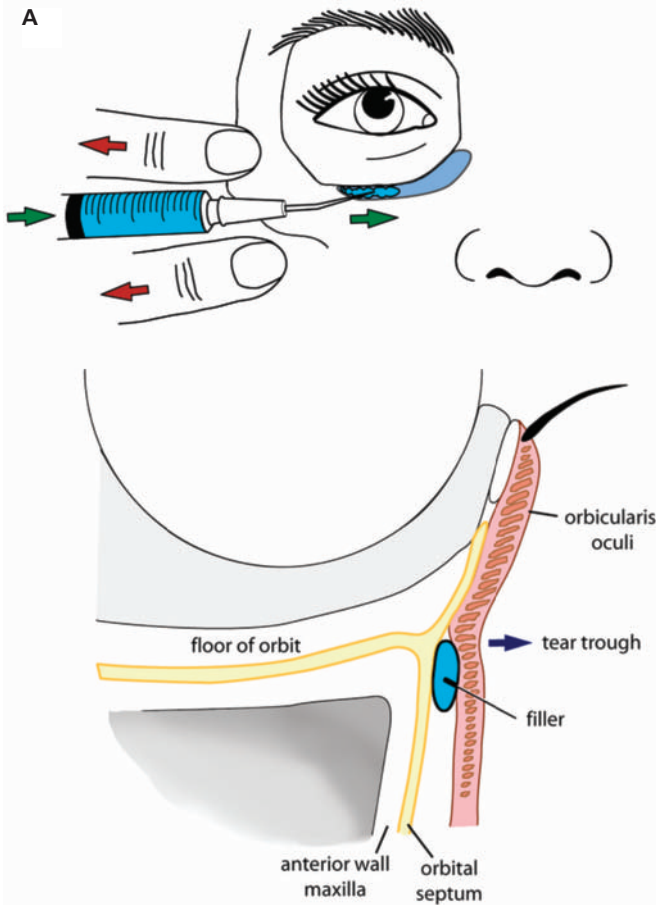


Figure 7. (A) Anatomic location of filler in this region is in the virtual space posterior to the orbicularis oculi muscle at the arcus marginalis. The injector should be able to feel periosteum with the tip of the needle and to use the push-ahead technique so that the filler insertion does not cause bruising. (B) Deep soft tissue augmentation (retro-orbicularis oculi) at the arcus marginalis to elevate the nasojugal fold.

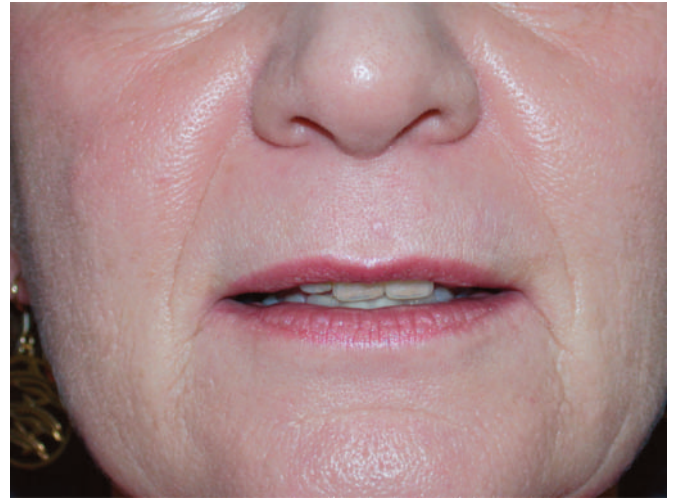

Figure 8. Treating the complete perioral frame and the vermilion lip enhances the positive effects of the perioral region.

injected on each side into the depressor anguli oris.³⁸ Both can be injected at the same treatment session if required.

Conclusion

In addition to their benefits in correcting rhytids and folds, fillers can be used to restore fullness that is naturally lost as fat and bone diminish from the face with aging, creating a more harmonious and esthetically appealing visage. With new techniques and materials, it is often difficult to decide which procedure or filling agent will provide the most optimum results with the fewest complications or side effects. Cosmetic patients—sophisticated consumers—are increasingly dissatisfied with less than ideal results or procedures that cause considerable interruption in their daily activities. In addition to a predictable esthetic outcome, safety and duration are of the utmost importance. Although the more traditional fillers are still used widely, newer agents—particularly hyaluronic acid derivatives and PMMA microspheres and collagen agents—have gained popularity and achieved wider accessibility. Their space-occupying properties are used to replace lost subdermal support and then provide brow, midface, and lower face augmentation with an almost instant enhancement of the projection and profile of the injected area. Unlike traditional surgical procedures, soft tissue augmentation addresses the increasing demand for less invasive treatments that can give a three-dimensional effect. Agents such as the hyaluronans may prove to be the ideal sculptural facial rejuvenation agents, producing a more natural and youthful countenance with greater safety and convenience for the esthetic subject.

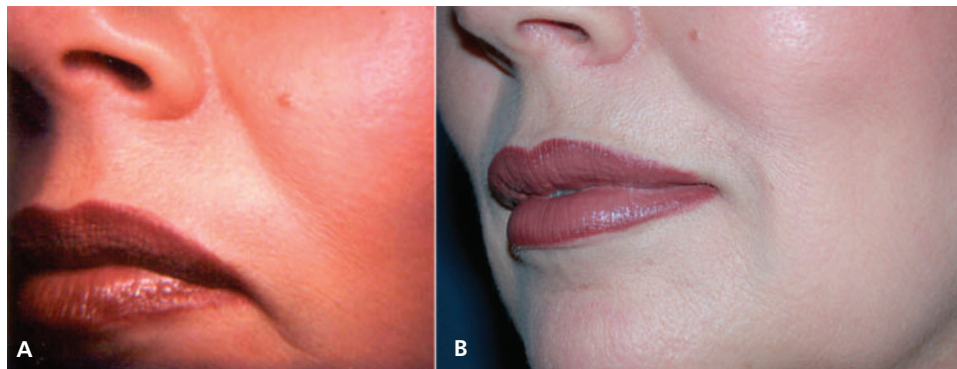

Figure 9. Esthetic improvement of the vermilion lip within the entire perioral frame using long-lasting but biodegradable hyaluronan (Restylane) (A, before; B, after enhancement of lip corners).

References

- Knize DM. An anatomically based study of the mechanism of eyebrow ptosis. *Plast Reconstr Surg* 1996;97:1321–33.
- Knize DM. Muscles that act on glabellar skin: a closer look. *Plast Reconstr Surg* 2000;105:350–61.
- Tardy ME, Alex J, Hendrick D. Rejuvenation of the aging brow and forehead. In: Putterman AM, Warren LA, Lampert R, editors. *Cosmetic oculoplastic surgery: eyelid, forehead, and facial techniques*. W.B. Saunders; 1999.
- Chiu ES, Baker DC. Endoscopic brow lift: a retrospective review of 628 consecutive cases over 5 years. *Plast Reconstr Surg* 2003;112:628–33.
- Donofrio LM. Fat distribution: a morphologic study of the aging face. *Dermatol Surg* 2000;26:1107–12.
- Reno WT. Reinforced orbitotemporal lift: contribution to midface rejuvenation. *Plast Reconstr Surg* 2003;111:869–77.
- Putterman AM. Cheek and midface lift combined with full-thickness temporal lower eyelid resection. In: *Cosmetic oculoplastic surgery: eyelid, forehead, and facial techniques*. 3rd ed. Philadelphia:W.B. Saunders, 1999. p. 235–47.
- Rounds MF, Cheney ML, Quatela VC. Endoscopic facial surgery. *Facial Plast Surg* 1998;14:217–26.
- Ramirez OM. Three-dimensional endoscopic midface enhancement: a personal quest for the ideal cheek rejuvenation. *Plast Reconstr Surg* 2002;109:329–40.
- Sullivan SA, Dailey RA. Endoscopic subperiosteal midface lift: surgical technique with indications and outcomes. *Ophthal Plast Reconstr Surg* 2002;18:319–30.
- Williams JV. Transblepharoplasty endoscopic subperiosteal midface lift. *Plast Reconstr Surg* 2002;110:1769–75.
- Yousif NJ, Matlob MD, Summers AN. The midface sling: a new technique to rejuvenate the midface. *Plast Reconstr Surg* 2002;110:1541–53.
- de Cordier BC, de la Torre JL, Al-Hakeem MS, et al. Rejuvenation of the midface by elevating the malar fat pad: review of techniques, cases, and complications. *Plast Reconstr Surg* 2002;110:1526–36.
- Owsley JQ Jr, Zweifler M. Midface lift of the malar fat pad: technical advances. *Plast Reconstr Surg* 2002;110:674–85.
- Coleman SR. Facial recontouring with liposuction. *Clin Plast Surg* 1997;24:347–67.
- Amar RE. [Adipocyte microinfiltration in the face or tissue restructuring with fat tissue graft]. *Ann Chir Plast Esthet* 1999;44:593–608.
- Donofrio LM. Structural autologous lipoaugmentation: a pan-facial technique. *Dermatol Surg* 2000;26:1129–34.
- Donofrio LM. Fat rebalancing: the new “facelift.” *Skin Ther Lett* 2002;7:7–9.
- Berman M. Rejuvenation of the upper eyelid complex with autologous fat transplantation. *Dermatol Surg* 2000;26:1113–6.
- Clarke DP, Hanke CW, Swanson NA. Dermal implants: safety of products injected for soft tissue augmentation. *J Am Acad Dermatol* 1989;21:992–8.
- INAMED. Available at: www.inamed.com (accessed Nov 2003).
- Kanchwala SK, Bucky LP. Facial fat grafting: the search for predictable results. *Facial Plast Surg* 2003;19:137–44.
- Honig JF, Brink U, Korabiowska M. Severe granulomatous allergic tissue reaction after hyaluronic acid injection in the treatment of facial lines and its surgical correction. *J Craniofac Surg* 2003;14:197–200.
- Butterwick KJ, Lack EA. Facial volume restoration with the fat autograft muscle injection technique. *Dermatol Surg* 2003;29:1019–26.
- Chajchir A, Benzaquen I. Fat-grafting injections for soft tissue augmentation. *Plast Reconstr Surg* 1989;84:921.
- Coleman SR. Long-term survival of fat transplants: controlled demonstrations. *Aesthetic Plast Surg* 1995;19:421.
- Narins RS, Brandt F, Leyden J, et al. A randomized, double-blind, multicenter comparison of the efficacy and tolerability of Restylane versus Zyplast for the correction of nasolabial folds. *Dermatol Surg* 2003;29:588–95.
- Carruthers J, Carruthers A. A prospective, randomized, parallel group study analyzing the effect of BTX-A (Botox) and nonanimal sourced hyaluronic acid (NASHA, Restylane) in combination compared with NASHA (Restylane) alone in severe glabellar rhytides in adult female subjects: treatment of severe glabellar rhytides with a hyaluronic acid derivative compared with the derivative BTX-A. *Dermatol Surg* 2003;29:802–9.
- Carruthers J, Carruthers A, Maberley D. Deep resting glabellar rhytides respond to BTX-A and Hylan B. *Dermatol Surg* 2003;29:539–44.
- Saylan Z. Facial fillers and their complications. *Aesthetic Surg J* 2003;23:221–4.
- Lowe NJ, Maxwell CA, Lowe P, et al. Hyaluronic acid skin fillers: adverse reactions and skin testing. *J Am Acad Dermatol* 2001;45:930–3.
- Toy BR, Frank PJ. Outbreak of *Mycobacterium abscessus* infection after soft tissue augmentation. *Dermatol Surg* 2003;29:971–3.
- Carruthers J, Klein AW, Carruthers A, et al. Safety and efficacy of Restylane™ for improvement of the mouth corners. *Dermatol Surg* 2005;31:276–80.
- Lemperle G, Hazan-Gauthier N, Lemperle M. PMMA microspheres (Artecoll) for skin and soft tissue augmentation. Part II: clinical investigations. *Plast Reconstr Surg* 1995;96:627–34.
- Lemperle G, Romano JJ, Busso M. Soft tissue augmentation with Artecoll: 10-year history, indications, techniques, and complications. *Dermatol Surg* 2003;29:573–87.
- Alcalay J, Alcalay R, Gat A, Yorav S. Late-onset granulomatous reaction to Artecoll. *Dermatol Surg* 2003;29:859–62.
- Pollack S. Some new injectable dermal filler materials: Hylaform, Restylane, and Artecoll. *J Cutan Med Surg* 1999;3 Suppl 4:S27–35.
- Lemperle G, Gauthier-Hazan N, Lemperle M. PMMA-microspheres (Artecoll) for long-lasting correction of wrinkles: refinements and statistical results. *Aesthetic Plast Surg* 1998;22:356–65.